

What is a TPLO

Your dog has torn the cranial cruciate ligament. Stabilization of this ligament is the most common procedure performed by the veterinary orthopedic surgeon. The cranial cruciate ligament is located inside the stifle (or knee) and is one of the four main stabilizing ligaments in the stifle joint. An intact cranial cruciate ligament is necessary to prevent forward and backward sliding of the femur on the tibia bone (cranial drawer motion).

Rupture of the cranial cruciate ligament affects all ages and breeds of dogs. Tearing of the cruciate ligament is often a gradual process (partial tear) and not simply due to a single traumatic event. Most dogs have a predisposing factor such as age-related ligament degeneration, pre-existing inflammation, anatomical abnormalities, or excessive slope of the top of the tibia, which cause the ligament to fail. Clinical signs of early cruciate ligament disease include stiffness or very mild lameness. As the disease advances and the ligament progressively tears, the lameness becomes more pronounced. Complete tears initially result in non-weight-bearing on the limb, but as time goes on the dog will start to use the limb. It is unusual for the lameness to totally resolve following a complete tear of cruciate ligament in a large breed dog unless surgery is performed. Rupture of the cranial cruciate ligament in both knees is common. In fact, almost one half of the dogs that have a TPLO performed will ultimately develop a cranial cruciate ligament tear involving the opposite stifle.

You have chosen a TPLO (tibial plateau leveling osteotomy) to stabilize your dog's torn cranial cruciate ligament. A simple model will help to illustrate how a TPLO works. The tibial plateau of a dog's stifle is normally sloped. Understanding the importance of the tibial slope when the cranial cruciate ligament is torn is somewhat difficult. A model of a wagon on a hill, which is tied to a fence post, will be used to help explain the procedure. The slope of the hill represents the tibial plateau, the wagon represents the femur bone, and the cable represents the cranial cruciate ligament. If the cable is torn, the wagon will roll down the hill (*Figure 1A*). Likewise, when the cranial cruciate ligament is torn the femur bone will slide down the slope of the tibial plateau. When the surface that the wagon is placed on is level and weight is put in the wagon, it does not roll backward (*Figure 1B*). In the dog, the tibial plateau leveling osteotomy levels the slope of the tibial plateau so that the femur no longer slides down the plateau. Thus a dynamically stable joint is created and instability is eliminated.

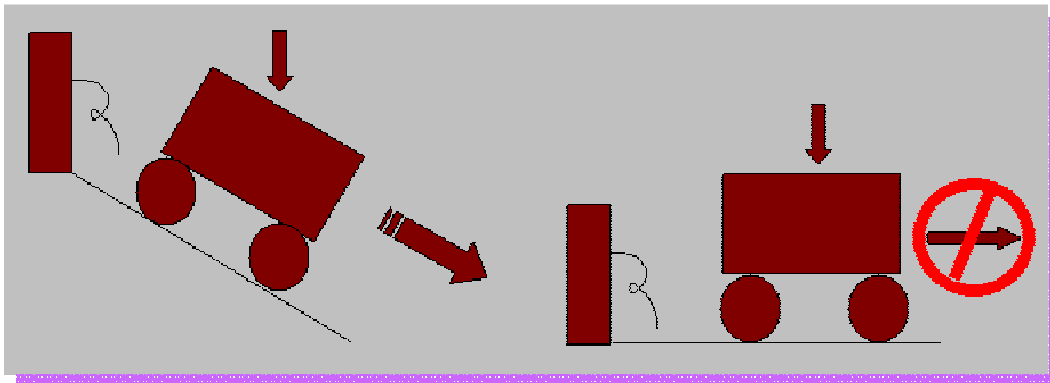


Figure 1A

Figure 1B

The TPLO surgery involves removing the torn ends of the cruciate ligament and examining the meniscus cartilage. If a tear involving the meniscus is found, the damaged component is removed. During the TPLO procedure a curved cut (osteotomy) is made in the top of the tibia that includes the tibial plateau. The tibial plateau (the dashed line denotes the top of

the tibial plateau) is then rotated along the curved osteotomy in order to level the slope (*Figure 2A*). A plate and screws are used to hold the tibial plateau in place so that the bone can heal. Below is an illustration (*Figure 2B*) demonstrating the curved cut in the tibia and rotation of the tibial plateau; also below (*Figure 3*) is photograph of a plastic bone model demonstrating the TPLO; take note of the metal plate and screws that hold the bone together while healing occurs.

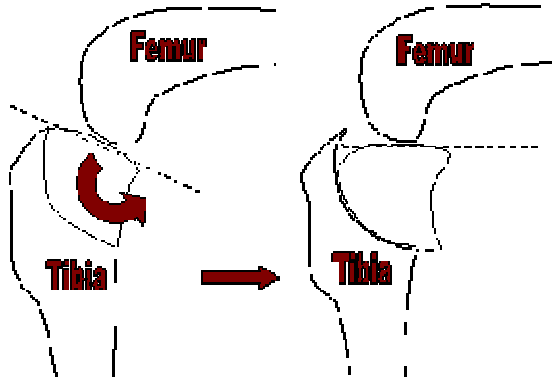


Figure 2A

Figure 2B

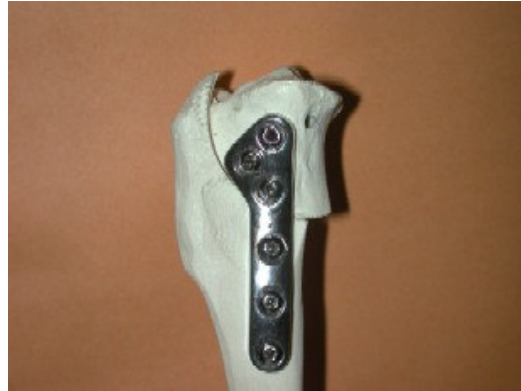

Figure 3

The majority of dogs having a TPLO achieves normal or near normal function of the limb (full weight-bearing). The dogs that do not have a full return of function often have concurrent arthritis of other joints on the affected limb or advanced degenerative joint disease in the affected stifle. However, most of the dogs in this group are still improved following the TPLO procedure.

As with any surgery, complications may arise. Some swelling and bruising around the surgical site are common, with both usually resolved within 7-10 days of surgery. Infection is an unusual complication as strict sterile technique is used during the surgery and antibiotics are administered during and following the procedure. If steroids are given to a pet for reasons such as skin allergies, healing of the bone may be impaired and susceptibility to infection increases. Poor healing or fracture of the bone, breakage of plates or screws or backing out of the screws can occur if the pet is too active, especially during the initial healing phase (first 2 months after surgery). If bone fracture or implant failure results in shifting of the slope of the tibial plateau, re-stabilization of the TPLO may be necessary. This complication is more common in the giant breed dog, and as a result we generally place a larger plate or plates in these animals to help prevent this problem. Those dogs that have significant complications postoperatively or have been previously operated using another technique may have a slower or incomplete recovery.

Arthritis usually is present in the affected stifle at the time of surgery. Unfortunately we cannot reverse the arthritic and degenerative state of the joint, but the surgery can help to minimize its progression. Clinical signs of arthritis include stiffness associated with heavy exercise or following rest, or during periods of cool or damp weather. Anti-inflammatory medications and chondroprotective medications may be helpful in ameliorating clinical signs.

Following the TPLO procedure the stifle joint is stable, with the bones no longer sliding or moving abnormally when the dog walks or runs. In ~12 weeks the bone cut (osteotomy) heals and the dog can return to normal activity. We have included a very specific list of postoperative care recommendations that, if followed, should give your dog the best chance for a complete and uneventful recovery.

Diagrams and photographs courtesy of: Dr. Daniel Degner and Vet Surgery Central Inc.